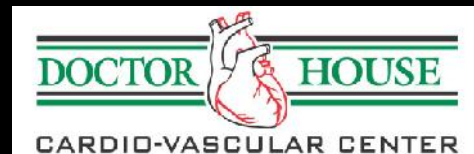

**WELCOME TO  
DOCTOR HOUSE  
CARDIO-VASCULAR CENTRE**

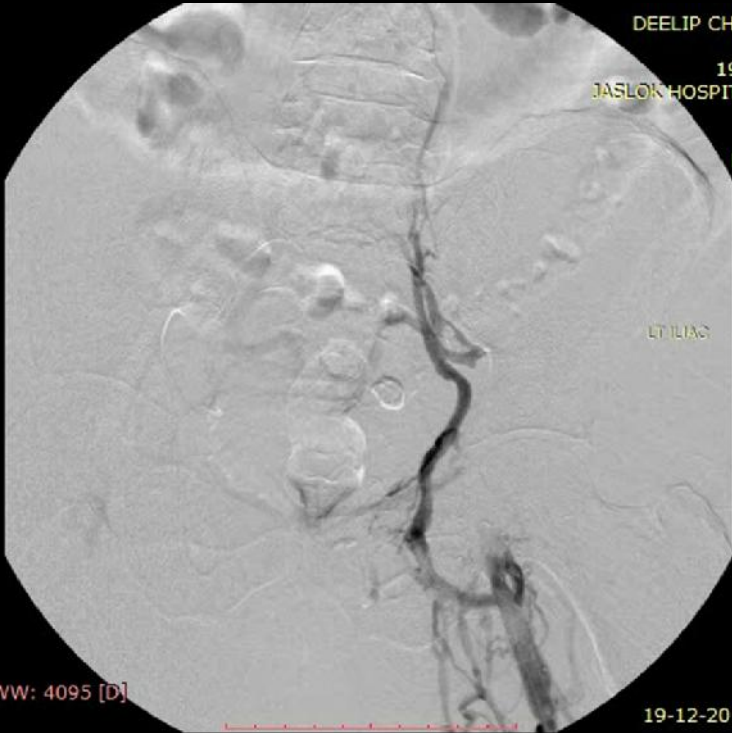**Long Standing  
Blockage of the Left  
Iliac vein**

**Due to  
Deep Vein  
Thrombosis  
in the Past**

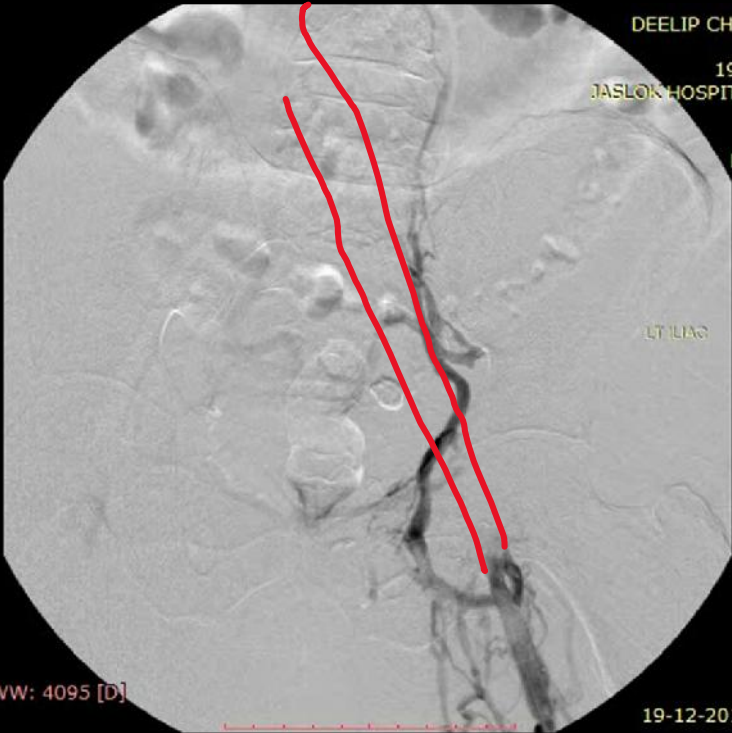


# Venography picture shows a fully blocked Left Iliac vein in the groin

Im: 1/2  
Se: 3

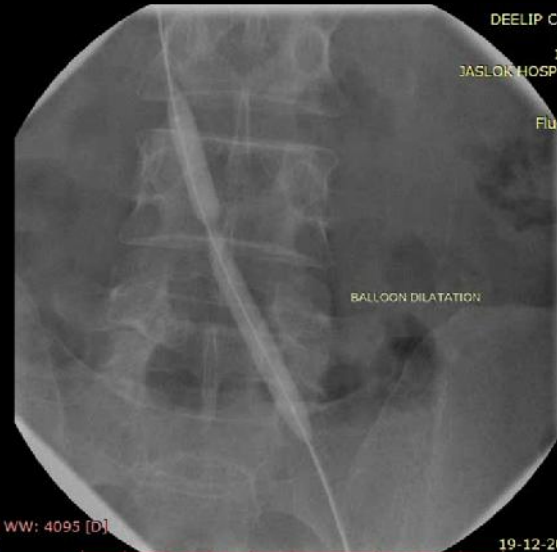

Im: 1/2  
Se: 3

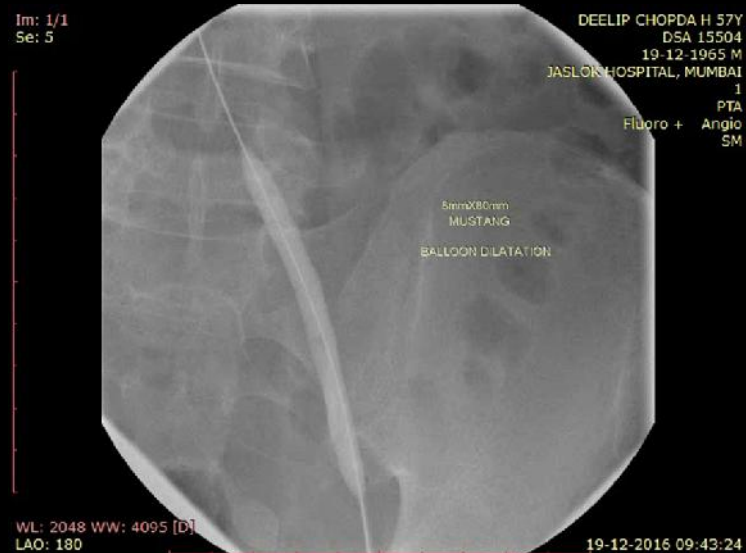

A wire is used to cross the blockage and balloon is used to dilate ( expand ) the blockage and create a passage for the blood

Im: 1/1  
Se: 8

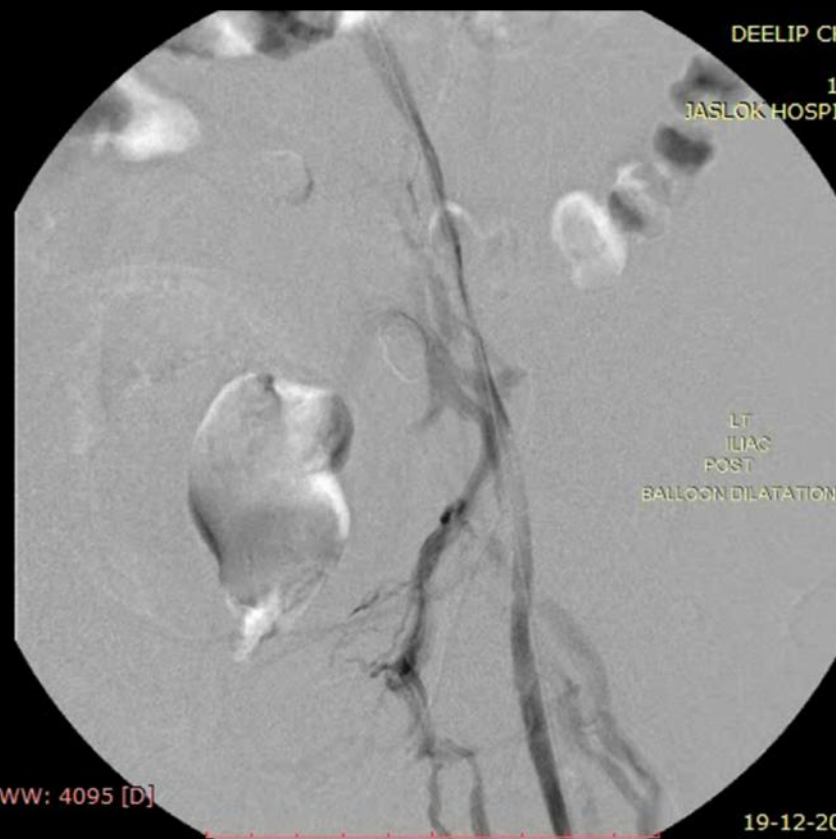

Im: 1/1  
Se: 5



Following the balloon dilatation, a channel is now created in the previously blocked left iliac vein

Im: 1/3  
Se: 10



DEELIP CHOPDA H 57Y  
DSA 15504  
19-12-1965 M  
JASLOK HOSPITAL, MUMBAI  
1  
PTA  
PERIPHERAL  
SM

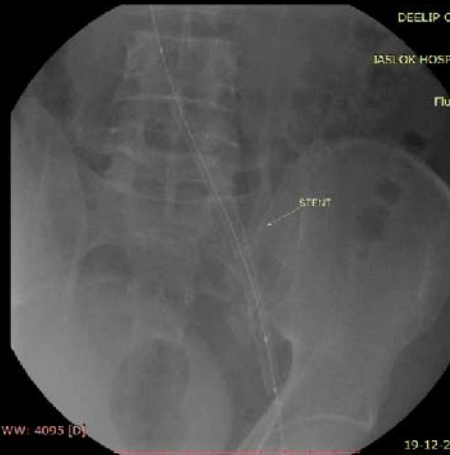LT  
ILIAC  
POST  
BALLOON DILATATION

WL: 2048 WW: 4095 [D]  
LAO: 180

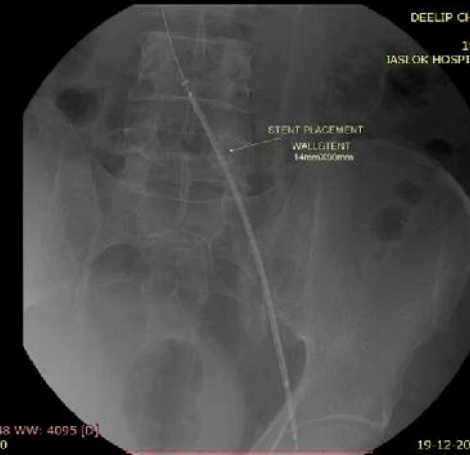19-12-2016 09:54:04

A Metallic Stent is now placed across the blockage, and opened up, to fully expand the vein

Im: 1/1  
Se: 19

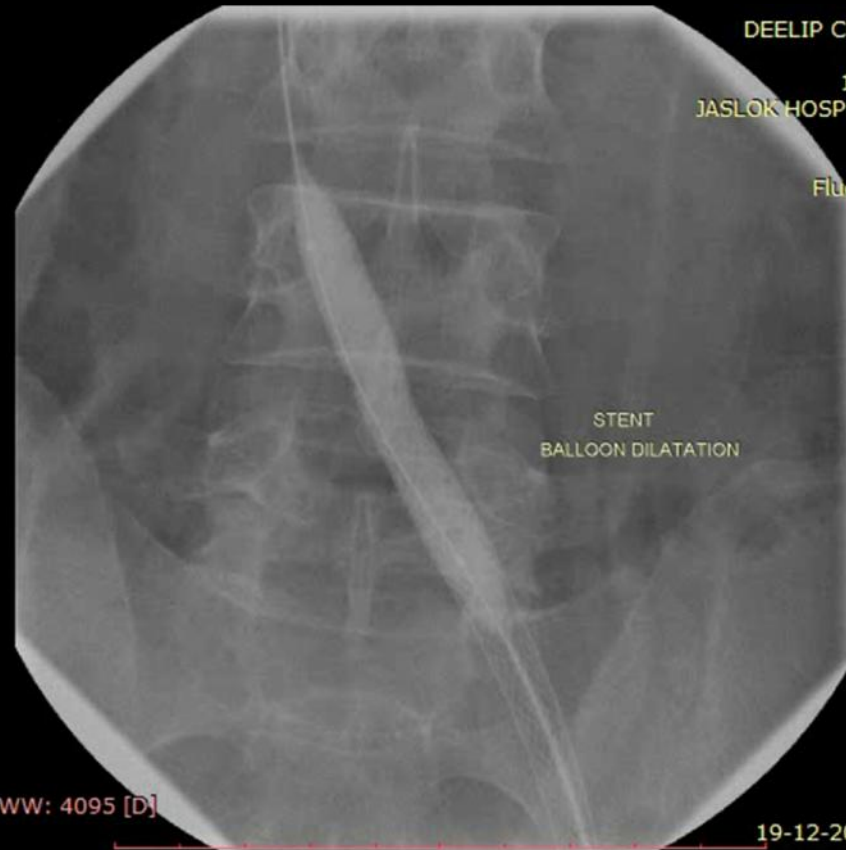

Im: 1/1  
Se: 18



The stent is then expanded by a balloon, so the stent is now fully opposed to the vein wall

Im: 1/1  
Se: 20



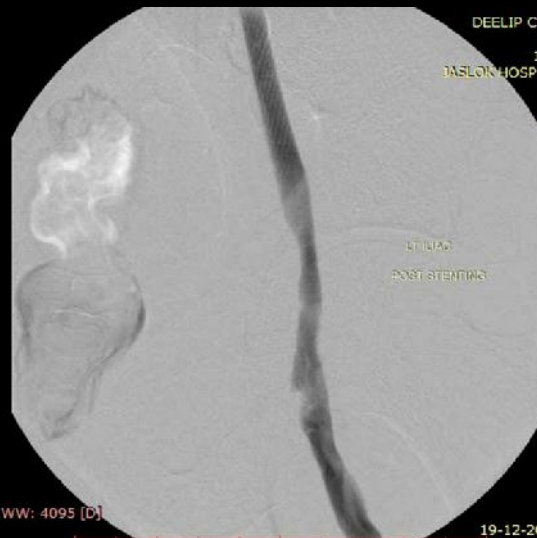DEELIP CHOPDA H 57Y  
DSA 15504  
19-12-1965 M  
JASLOK HOSPITAL, MUMBAI  
1  
PTA  
Fluoro + Angio  
SM

WL: 2048 WW: 4095 [D]  
LAO: 180

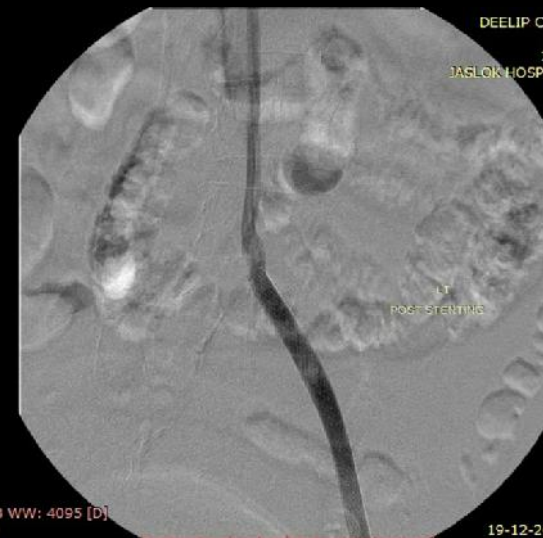19-12-2016 10:14:22

Final  
venography  
picture shows  
fully opened  
up Left Iliac  
Vein

Im: 1/2  
Se: 31



Im: 1/1  
Se: 24



# Thank You For Watching Presentation

207, Doctor House Opposite Jaslok Hospital  
Pedder Road, Mumbai 400026.

**Contact: +91 22 23525001 / 23526001**

**Email:**  
[info@varicose.in](mailto:info@varicose.in) / [dhcvcindia@gmail.com](mailto:dhcvcindia@gmail.com)

**Website: [www.varicose.in](http://www.varicose.in)**

